

**Title:** A Case Report of Acute Severe Myelitis and Meningitis Secondary to Varicella Zoster Virus Reactivation in a Patient with Acquired Immunodeficiency Syndrome

**Author names:** Victor A. Novelo-Hernández<sup>1</sup>, Marco Cárdenas<sup>2</sup>, Claudia Torres-González<sup>1</sup>, Patricio García-Espinosa<sup>1</sup>, Rómulo Ramírez<sup>2</sup>, Marco Díaz-Torres<sup>2</sup>, Alejandro Marfil-Rivera<sup>2</sup>

**Degrees:** Medical Student., M.D., M.D, M.D, Medical Student, M.D., M.D., PhD

**Affiliations:** <sup>1</sup>School of Medicine, Universidad Autónoma de Nuevo León, Monterrey. México, <sup>2</sup>Neurology Service, “University Hospital “José Eleuterio González”, Universidad Autónoma de Nuevo Leon, Monterrey. México.

**About the author:** Victor Novelo is currently a fifth-year medical student of UANL medical school, Monterrey, Mexico. He is also first place of his medical generation.

Marco Cárdenas. He is currently a neurology third year resident at UANL medical school, Monterrey, Mexico. He is also the current neurology resident chief.

Claudia Torres-González. She is currently a social service medical intern student at UANL medical school, Monterrey, Mexico.

García-Espinosa, P. He is currently a sixth-year medical student of UANL medical school, Monterrey, Mexico of a six-year program. He is also current leader of GECEN researchers (Group of students against neurological diseases, undergraduate neurology department arm).

Rómulo-Ramirez. He is currently a neurology professor at University Hospital “Dr. José Eleuterio González” UANL, neurology service.

Marco Díaz-Torres. He is currently a neurology professor at University Hospital “Dr. José Eleuterio González” UANL, neurology service.

Alejandro Marfil-Rivera. He is currently a neurology professor at University Hospital “Dr. José Eleuterio González” UANL, neurology service, also he is part of National System of Investigators (SNI I).

**Acknowledgment:** Fernando Góngora-Rivera and Ingrid Estrada-Bellmann. Neurology Department professors who help us with comments.

**Financing:** Any relevant founding was received from any source for this manuscript.

**Conflict of interest statement by authors:** Authors declare they don't have any conflict of interest.

**Compliance with ethical standards:** the authors stated they retain informed consent signed by the patient authorizing the data publication and that the manuscript is by the Institutional Ethics rules

### Authors Contribution Statement:

<Contributor Role	Role Definition	Authors						
		1	2	3	4	5	6	7
<b>Conceptualization</b>	Ideas; formulation or evolution of overarching research goals and aims.	X						X
<b>Data Curation</b>	Management activities to annotate (produce metadata), scrub data and maintain research data (including software code, where it is necessary for interpreting the data itself) for initial use and later reuse.	X		X		X		
<b>Formal Analysis</b>	Application of statistical, mathematical, computational, or other formal techniques to analyze or synthesize study data.	X						X
<b>Funding Acquisition</b>	Acquisition of the financial support for the project leading to this publication.						X	
<b>Investigation</b>	Conducting a research and investigation process, specifically performing the experiments, or data/evidence collection.		X		X	X	X	X

<b>Methodology</b>	Development or design of methodology; creation of models									X
<b>Project Administration</b>	Management and coordination responsibility for the research activity planning and execution.	X	X	X	X	X				
<b>Resources</b>	Provision of study materials, reagents, materials, patients, laboratory samples, animals, instrumentation, computing resources, or other analysis tools.		X			X	X	X		X
<b>Software</b>	Programming, software development; designing computer programs; implementation of the computer code and supporting algorithms; testing of existing code components.				X	X	X			
<b>Supervision</b>	Oversight and leadership responsibility for the research activity planning and execution, including mentorship external to the core team.	X	X			X				X
<b>Validation</b>	Verification, whether as a part of the activity or separate, of the overall replication/reproducibility of results/experiments and other research outputs.	X	X	X	X	X				
<b>Visualization</b>	Preparation, creation and/or presentation of the published work, specifically visualization/data presentation.	X	X	X	X	X	X	X	X	X
<b>Writing – Original Draft Preparation</b>	Creation and/or presentation of the published work, specifically writing the initial draft (including substantive translation).	X	X	X	X	X	X	X	X	X
<b>Writing – Review &amp; Editing</b>	Preparation, creation and/or presentation of the published work by those from the original research group, specifically critical review, commentary or revision – including pre- or post-publication stages.	X	X	X	X	X				

1  
2  
3  
4  
5  
6  
7  
8  
9  
10  
11  
12  
13  
14  
15  
16  
17  
18  
19  
20  
21

### Highlights:

- Post-herpes Zoster myelitis is a very uncommon presentation.
- This case presents the importance of screening for undetected HIV infections.
- Introduction of clinical and images to improve curiosity about the case.

**Manuscript word count:** 1383

**Abstract word count:** 186

**Number of Figures and Tables:** 2

### Personal, Professional, and Institutional Social Network accounts.

- <https://www.facebook.com/victor.novelo.146>
- <https://www.facebook.com/patricio.garciaespinosa/>
- <https://twitter.com/patricio240498>
- <https://twitter.com/uanl>

**Publisher's Disclosure:** *This is a PDF file of an unedited manuscript that has been accepted for publication. As a service to our readers and authors we are providing this early version of the manuscript. The manuscript will undergo copyediting, typesetting, and review of the resulting proof before it is published in its final citable form. Please note that during the production process errors may be discovered which could affect the content, and all legal disclaimers that apply to the journal pertain.*

1 **ABSTRACT**  
2

3 **Background:** Myelitis post Herpes-Zoster is a rare condition that is typically associated with  
4 immunocompromised states. It usually starts as an acute loss of sensory and motor functions below the affected  
5 spinal cord level. The condition can range in severity from a mild to a fatal presentation. Other neurological  
6 complications include meningitis, atypical presentations should encourage the search for undiagnosed  
7 immunosuppression states.  
8

9 **The Case:** We describe the case of a 42-year-old man, previously undiagnosed with HIV, who developed acute  
10 myelitis and meningitis after the appearance of the classic zoster lesions. On lumbar puncture and subsequent  
11 CSF analysis, the patient was found to have Froin's Syndrome. The patient was initiated with ceftriaxone,  
12 vancomycin, and acyclovir regimen and prophylactic antiphytic treatment was also added. After 14 days in the  
13 hospital, the fever, headache, and neck stiffness subsided while the sphincter function and lower limb paraplegia  
14 did not improve.  
15

16 **Conclusion:** Varicella zoster virus reactivation suggests underlying immunosuppression. This case  
17 demonstrates the importance of being cognizant to the wide range of clinical manifestations that may suggest  
18 spinal cord involvement after clinical reactivation. Furthermore, physicians also need to be mindful that Acquired  
19 Immunodeficiency Syndrome (AIDS) and other immunodeficiency states could present with atypical clinical  
20 manifestations.  
21

22  
23  
24 **Key Words:** : Immunosuppression; Myelitis; HIV; Acquired Immunodeficiency Syndrome; Varicella-Zoster Virus  
25 Infection; Herpes Zoster (Source: MeSH-NLM).  
26  
27

## 1 INTRODUCTION

2  
3 Varicella-Zoster Virus (VZV) is a highly infectious, exclusively human virus with worldwide prevalence. Primary  
4 infection of VZV leads to acute varicella and after primary infection, the virus is established on a cranial nerve  
5 and dorsal root ganglia with a lifelong latency.<sup>1</sup> Reactivation leads to Herpes Zoster (HZ) which presents as an  
6 exanthem of vesicular lesions in a dermatomal distribution and is highly painful, HZ is an opportunistic infection  
7 with an increased risk in patient who are immunocompromised.<sup>1</sup> However the incidence of HZ has decreased  
8 in HIV/AIDS patients since the introduction of antiretroviral therapy (from 2,955 per 100,000 in 1992-1996 to  
9 628 per 100,000 between 2009 and 2011).<sup>2</sup> Neurological complications secondary to HZ can occur, with  
10 meningitis being the most frequent.<sup>3</sup>

11  
12 Myelopathy is a less common neurological complication secondary to HZ, with an estimated incidence of less  
13 than 1 per 1,000 cases and affects most often immunocompromised patients or older patients in general,  
14 representing less than 0.3% among the patients with HZ virus infection.<sup>4</sup>

15  
16 The onset of HZ myelitis is usually acute or subacute, usually occurring after two weeks of vesicular rash  
17 appearance.<sup>4</sup> The pathophysiology is still unknown, but tissue findings include inflammation with mononuclear  
18 infiltration and microglial proliferation, hemorrhagic necrosis, and degeneration of both motor and sensory  
19 roots.<sup>4</sup> Additionally, cellular immunity deficits seen in AIDS may lead to a fatal form of myelitis, with spinal cord  
20 infarction, or progression of the disease and involvement of the diaphragm.<sup>5</sup> Commonly it presents as a mild  
21 and self-limited syndrome, but the spinal cord can become severely inflamed and cause serious complications  
22 such as recurrent HZ myelitis, loss of sensation and ability to ambulate, bacterial superinfection, postherpetic  
23 neuralgia, and fatal myelitis that is mostly seen in immunocompromised patients.<sup>6,7</sup>

24  
25 Froin's syndrome is defined by the presence of xanthochromia (yellow or pink color), the elevation of protein  
26 levels (>500 mg/dl), and hypercoagulation state on CSF cytology, and is an unusual condition that is presented  
27 after irritation and blockage of CSF (usually due to a mass or abscess). The combination of these three signs  
28 is considered pathognomonic; due to the effect on the spinal cord, the neurologic examination could expose  
29 paralysis of the lower limbs, decreased sensation, and other components of myelopathy.<sup>8</sup>

30  
31 Here, we present the case of an AIDS patient with meningitis and severe myelitis due to VZV reactivation, with  
32 a less described presentation, and this also represents one of the few reported cases that developed Froin's  
33 syndrome (FRS).

34  
35 The reported cases of FRS, in the context of a CNS invasion by VZV, are mostly related to encephalitis, with  
36 only one case associated with myelitis. VZ myelitis usually presents in more advanced age, as in the case  
37 presented by Kleinschmidt-DeMaster *et al*, wherein 2016 they presented the case of 54-year-old man with a  
38 known history of several comorbidities.<sup>9</sup> In our case, the patient was apparently healthy before, as he was only  
39 known to have high blood pressure and was diagnosed with HIV after the onset of the symptomatology.<sup>9</sup>

**THE CASE.**

A 42-year-old man complaining of burning constant pain with distribution in T8-T10 dermatome was admitted to the emergency department. The pain did not radiate and did not have any aggravating nor relieving factors. The pain started 10 days before his admission, in the aforementioned dermatomes, with subsequent appearance of vesicles and erythema in the same zone (Figure 1). The oppressive holocranial headache appeared 72 hours before admission, with occipital predominance, and was accompanied by symptoms of fever, vomiting, urinary retention, and lower limb weakness. The patient has a history of systemic arterial hypertension, alcoholism, and an exploratory laparotomy with cystography 20 years ago secondary to abdominal trauma.

On examination, there was moderate paraparesis (3/5 Medical Research Council scale, MRC) and neck stiffness, with the rest of the exam unremarkable. These findings raised the suspicion of a central nervous system (CNS) infectious process, so the patient underwent a cranial simple computed tomography (CT), lumbar puncture, viral panel. Empiric treatment for meningitis was initiated (ceftriaxone 2g IV q12h, vancomycin 1g IV q8h, acyclovir 750 mg IV q8h).

The viral panel was performed and positive for HIV-1 and the cluster of differentiation 4 (CD4) count was markedly low (104 cells/uL). The CT scan showed no pathological changes, but the lumbar puncture demonstrated xanthochromia, pleocytosis with lymphocyte predominance, hyper proteinorachie (1430 mg/dl), hypoglycorrhachia (21 mg/dl), and hypercoagulation, consistent with viral meningitis and Froin's Syndrome. BioFire® meningitis/encephalitis panel was performed with a positive result for VZV. Because of the condition, coinfection with bacteria or mycobacteria could not be ruled out, so antiphymic treatment (doTbal®) was added, and cultures for fungi and mycobacteria were obtained. A GeneXpert® MTB/RIF test was run with a negative result. GeneXpert® MTB/RIF is a real-time polymerase-chain-reaction-based (RT-PCR) method used for rapid and accurate detection of active tuberculosis and to determine resistance for rifampicin. The decision was made to discard extrapulmonary tuberculosis as an etiological agent or tuberculosis as a coinfection (tuberculosis is considered endemic in the author's state). RT-PCR performed to detect the presence of VZV resulted positive.

On the second day of hospitalization, the patient developed bowel incontinence and an increase in the lower limb weakness (2/5 MRC) with anesthesia. This raised the suspicion of inflammatory myelitis and treatment with methylprednisolone was initiated (1 g IV q24h for 5 days). Magnetic resonance imaging (MRI) of the dorsal spine was performed showing a widened spinal cord at T4-T7 levels, with hydrosyringomyelia above this level (T1-T4) and a T2 weighted hyperintensity zone near the conus medullaris (T11-L1). This established the diagnosis of acute transverse myelitis (Figure. 2 A, B).

After 14 days in the hospital and treatment with ceftriaxone, vancomycin, acyclovir and, doTbal®, the patient was discharged with outpatient follow-up. The fever, headache, and neck stiffness subsided, but sphincter function and lower limb paraplegia did not improve.

## 1 DISCUSSION

2  
3 This case report was about disseminating how atypical clinical symptoms of myelitis are in patients with HZ  
4 reactivation, in addition to the complications that these reactivations can have on a patient's lifestyle as a result  
5 of not improving after treatment,  
6

7 Post HZ myelitis and meningitis are rare, but very well described CNS complications.<sup>9</sup> The infection of the  
8 meninges has a clinical presentation easy to recognize and is more common than myelitis in the  
9 immunocompetent population.<sup>9,10</sup>  
10

11 The HZ myelitis, besides being rarer than meningitis, tends to be harder to suspect due to the clinical  
12 presentation, which tends to be atypical in patients with decreased immune function.<sup>10</sup> HZ myelitis usually  
13 manifests as an acute onset of sensory loss, focal weakness, and sphincter dysfunction (bladder dysfunction  
14 being more common than bowel) below the affected level.<sup>10</sup>  
15

16 Immunocompromised patients tend to have atypical presentations of Herpes Zoster, even without the  
17 appearance of characteristic herpetic skin lesions and may show a variation in the temporal relationship  
18 between these lesions and the medullary symptoms (usually 1-2 weeks).<sup>10</sup> However, the frequency of  
19 topographic dissociation between the affected dermatomes and the level of the myelitis is not significantly  
20 different with immunocompetent patients.<sup>10</sup> In this case, the patient presented with urinary retention (described  
21 more in sacral spine involvement) and bowel incontinence, two features that are less common, but equally  
22 important to consider, especially if other typical symptoms do not appear.<sup>4</sup>  
23

24 To confirm the diagnosis, VZV DNA and VZV IgG detection by real-time PCR and serology, respectively, are  
25 the methods of choice, and must be done at the same time.<sup>11</sup> DNA decreases within the first 7 days of  
26 symptomatology start while antibodies increase proportionally.<sup>12</sup> Serology must be measured on paired serum  
27 and CSF.<sup>12</sup> The typical MRI findings include T2 hyperintensities and focal swelling, sometimes large enough to  
28 occlude the subarachnoid space, which, like in this case, caused Froin's syndrome, which is characterized by  
29 the triad of xanthochromia, elevation of protein levels (>500 mg/dL), and hypercoagulation state as well as the  
30 clinical manifestations of myelopathy.<sup>13,14</sup> It is believed that the hypercoagulation state is responsible for starting  
31 a series of diffusion processes that lead to the aforementioned findings of FRS.<sup>14,15</sup> The reported cases of FRS,  
32 in the context of a CNS invasion by VZV, are mostly related to encephalitis, with only one case associated with  
33 myelitis, but none have been found to be associated with myelitis and meningitis simultaneously, which makes  
34 this case unique.<sup>5,16,17</sup>  
35

36 Standard treatment has not been established, and some authors have proposed the use of acyclovir combined  
37 with a corticosteroid regimen, while others opt for the single use of antivirals, with differences and  
38 inconsistencies in the outcomes.<sup>8,9,14,15</sup> This explains the need to carry out more specific studies that allow for  
39 establishing a treatment that improves the prognosis of these patients.  
40

1 This case highlights the importance of focusing on the whole range of manifestations that may suggest a spinal  
2 cord involvement following Herpes Zoster reactivation. It shows the importance of suspecting this condition in  
3 immunocompromised patients, in whom the disease can cause excessive inflammation and progress rapidly  
4 towards a fatal outcome or important sequelae. In this specific context, it is necessary to be cognizant about  
5 multiple differential diagnoses with a wide range of possible etiological agents that can lead to confusion and  
6 delay in beginning a specific treatment may improve the clinical outcome.

Accepted, in-press

1 **REFERENCES**

- 2 1. Pergam SA, Limaye AP; AST Infectious Diseases Community of Practice. Varicella zoster virus (VZV)  
3 in solid organ transplant recipients. *Am J Transplant.* 2009 Dec;9 Suppl 4(Suppl 4):S108-15.
- 4 2. Grabar S, Tattevin P, Selinger-Leneman H, de La Blanchardiere A, de Truchis P, Rabaud C, et al.  
5 Incidence of herpes zoster in HIV-infected adults in the combined antiretroviral therapy era: results from  
6 the FHDH-ANRS CO4 cohort. *Clin Infect Dis.* 2015 Apr 15;60(8):1269-77.
- 7 3. Chamizo FJ, Gilarranz R, Hernández M, Ramos D, Pena MJ. Central nervous system infections caused  
8 by varicella-zoster virus. *J Neurovirol.* 2016 Aug;22(4):529-32.
- 9 4. Gildea D, Nagel MA, Cohrs RJ, Mahalingam R. The variegated neurological manifestations of varicella  
10 zoster virus infection. *Curr Neurol Neurosci Rep.* 2013 Sep;13(9):374.
- 11 5. Corti M, Trione N, Villafañe MF, Risso D, Yampolsky C, Mamanna L. Acute meningoencephalomyelitis  
12 due to varicella-zoster virus in an AIDS patient: report of a case and review of the literature. *Revista da*  
13 *Sociedade Brasileira de Medicina Tropical.* 2011 Oct;44:784-6.
- 14 6. Agrawal MM, Mahajan RS, Bilimoria FE, Ninama KR. Myelitis: A Rare Neurological Complication of  
15 Herpes Zoster. *Indian J Dermatol.* 2016 Nov;61(6):687-9.
- 16 7. Nakano T, Awaki E, Araga S, Takai H, Inoue K, Takahashi K. Recurrent herpes zoster myelitis treated  
17 with human interferon alpha: A case report. *Acta Neurol Scand.* 1992 May;85:372-5.
- 18 8. Dancel R, Shaban M. IMAGES IN CLINICAL MEDICINE. Froin's Syndrome. *N Engl J Med.* 2016 Mar  
19 17;374(11):1076.
- 20 9. Kleinschmidt-DeMasters BK, Mahalingam R, Shimek C, Marcoux HL, Wellish M, Tyler KL, Gildea DH.  
21 Profound cerebrospinal fluid pleocytosis and Froin's Syndrome secondary to widespread necrotizing  
22 vasculitis in an HIV-positive patient with varicella zoster virus encephalomyelitis. *J Neurol Sci.* 1998 Aug  
23 14;159(2):213-8.
- 24 10. Kim SH, Choi SM, Kim BC, Choi KH, Nam TS, Kim JT, Lee SH, Park MS, Kim SJ. Risk Factors for  
25 Aseptic Meningitis in Herpes Zoster Patients. *Ann Dermatol.* 2017 Jun;29(3):283-287.
- 26 11. Hung CH, Chang KH, Kuo HC, Huang CC, Liao MF, Tsai YT, Ro LS. Features of varicella zoster virus  
27 myelitis and dependence on immune status. *J Neurol Sci.* 2012 Jul 15;318(1-2):19-24.
- 28 12. Kedar S, Jayagopal LN, Berger JR. Neurological and Ophthalmological Manifestations of Varicella  
29 Zoster Virus. *J Neuroophthalmol.* 2019 Jun;39(2):220-231.
- 30 13. Noaillon M, Breining A, Greffard S, Sagot C, Verny M. Post-Herpes zoster myelitis in a very old patient:  
31 A complication not to be missed. *Geriatr Gerontol Int.* 2016 Jan;16(1):145-6.
- 32 14. Garispe A, Naji H, Dong F, Arabian S, Neeki M. Froin's Syndrome Secondary to Traumatic and  
33 Infectious Etiology. *Cureus.* 2019 Dec 6;11(12):e6313.
- 34 15. Greenfield JG. Original Papers: ON FROIN'S SYNDROME, AND ITS RELATION TO ALLIED  
35 CONDITIONS IN THE CEREBROSPINAL FLUID. *J Neurol Psychopathol.* 1921 Aug;2(6):105-41.
- 36 16. Kennedy PG. Issues in the Treatment of Neurological Conditions Caused by Reactivation of Varicella  
37 Zoster Virus (VZV). *Neurotherapeutics.* 2016 Jul;13(3):509-13.
- 38 17. Abbas SA, El Helou J, Chalah MA, Hilal H, Saliba G, Abboud H, et al. Longitudinal Extensive Transverse  
39 Myelitis in an Immunocompetent Older Individual-A Rare Complication of Varicella-Zoster Virus  
40 Reactivation. *Medicina (Kaunas).* 2019 May 23;55(5):201.



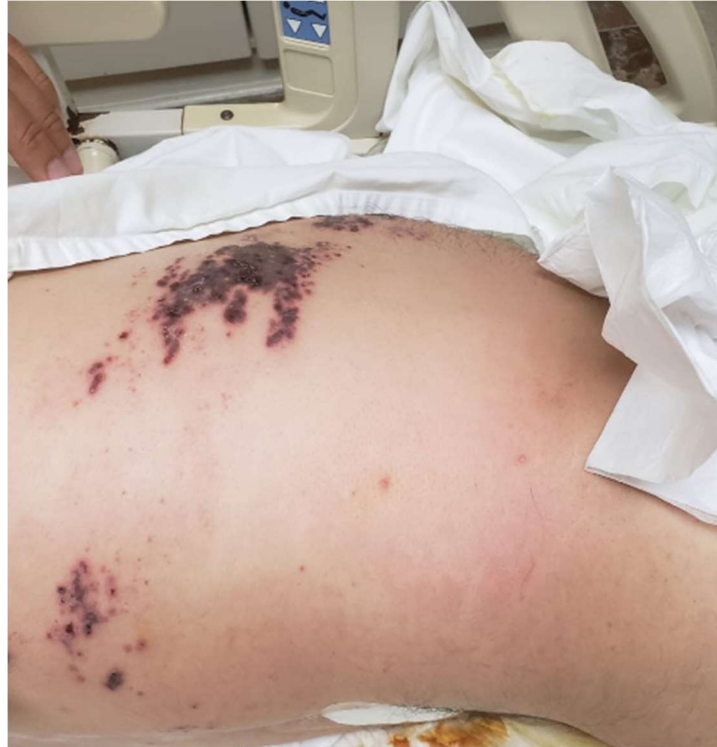1 **FIGURES AND TABLES.**

2

3 **Figure 1. Herpes-Zoster distribution.**

4 Vesicles and erythema in a dermatomal distribution (T8-10) associated with the clinical symptomatology  
5 established the clinical diagnosis of herpes zoster in this patient.

6



7

8

9

10

11

12

13

14

15

16

17

18

19

20

21

22

23

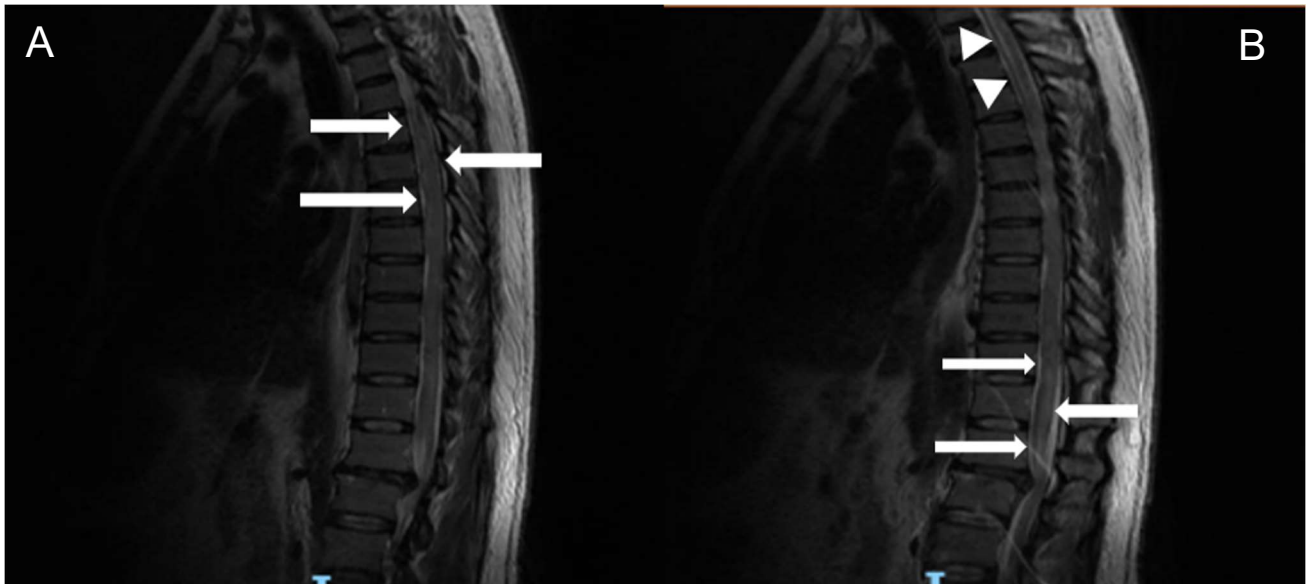
24

25

1  
2  
3  
4  
5  
6

**Figure 2. Magnetic Resonance Imaging.**

(A) Sagittal T2 weighted MRI of dorsal spine showing a widened spinal cord at T4-T7 levels (arrows). (B) Different view of sagittal section, T2 weighted MRI of dorsal spine showing hydro-syringomyelia at T1-T4 levels (arrowheads) and a hyperintensity zone at levels T11-L1 (arrows)



7  
8  
9  
10  
11  
12  
13  
14  
15  
16  
17  
18  
19  
20  
21  
22

Accepted,