

1 **Title:** A Cadaveric Study on the Anomalous Origin of Renal and Gonadal Vasculature: An Observational Study.

2
3 **Article type:** Original Article.

4
5 **Author names:**

- 6 1. Penelope C. Farris*
7 2. Dylan M. Macciola*
8 3. Lauren N. Baranzani
9 4. Justin R. Nathan
10 5. Danielle Quinn
11 6. Daniel F. Peters

12
13 **Degrees and Affiliations:**

- 14 1. B.S. Fourth-year Medical Student. New York Medical College, Valhalla, United States of America.
15 2. B.S. Fourth-year Medical Student. New York Medical College, Valhalla, United States of America.
16 3. M.S. Fourth-year Medical Student. New York Medical College, Valhalla, United States of America.
17 4. B.A. Fourth-year Medical Student. New York Medical College, Valhalla, United States of America.
18 5. M.D. Emory University, Atlanta, United States of America.
19 6. M.D. New York Medical College, Valhalla, United States of America.

20
21 **ORCID (Open Researcher and Contributor Identifier):**

- 22 <https://orcid.org/0000-0001-8836-3233>
23 <https://orcid.org/0000-0002-3167-963X>
24 <https://orcid.org/0000-0003-3240-0239>
25 <https://orcid.org/0000-0001-6954-8371>
26 <https://orcid.org/0000-0003-0494-9953>
27 <https://orcid.org/0000-0002-7721-8302>

28
29 **About the author:** Authors 1-4 are current medical students at New York Medical College in Valhalla, New
30 York, Author 5 is a resident at Emory University Hospital, and Author 6 is the Foundational Science Course
31 Director for Anatomy and Embryology at New York Medical College.

32 **Corresponding author email:** Dylan.macciola@gmail.com

33
34 **Acknowledgment:** Roger B. Bender MPH provided cadaver demographic data for the Department of Anatomy
35 and Cell biology at New York Medical College for the years 2018-2019.

36
37 **Financing:** No financial support was received to complete this study.

38 **Conflict of interest statement by authors:** All authors declare no conflicts of interest.

39
40 **Compliance with ethical standards:** This study has authorization for use of cadaveric images for educational
41 publications. This study does not contain any identifiable patient data which would require informed consent.

1
2
3
4
5
6
7
8
9
10
11
12
13
14
15
16
17
18
19
20
21
22
23
24
25
26
27
28
29
30
31
32
33
34
35
36
37
38
39
40
41

Authors Contribution Statement:

Penelope Farris: Writing – Original Draft, Writing – Review & Editing **Dylan Macciola:** Writing – Original Draft, Writing, Review & Editing **Lauren Baranzani:** Writing – Original Draft **Justin Nathan:** Writing – Original Draft **Danielle Quinn:** Writing – Original, Conceptualization Draft **Daniel Peters:** Supervision

Manuscript word count: 3,908

Abstract word count: 162

Number of Figures and Tables: 2

Personal, Professional, and Institutional Social Network accounts.

- **Facebook:** @nymedcollege
- **Twitter:** @nymedcollege
- **Instagram:** @nymedcollege

Discussion Points:

- Why should we know about the anomalous origin of renal and gonadal vessels? #Anatomy #Dissection #MedicalStudents
- One thing to be on the lookout for when considering donating a kidney #Anatomy #MedicalStudents

Dates

Submission: 09/21/2020

Revisions: 10/28/2020, 04/09/2021

Responses: 01/25/2021, 02/01/2022

Acceptance: 07/15/2022

Publication: 07/18/2022

Editors

Associate Editor/Editor: Francisco J. Bonilla-Escobar

Student Editors: Purva Shah, Lourdes Adriana Medina-Gaona & Vinson Chan

Copyeditor: Joseph Tonge

Proofreader:

Layout Editor:

Publisher's Disclosure: This is a PDF file of an unedited manuscript that has been accepted for publication. As a service to our readers and authors we are providing this early version of the manuscript. The manuscript will undergo copyediting, typesetting, and review of the resulting proof before it is published in its final citable form. Please note that during the production process errors may be discovered which could affect the content, and all legal disclaimers that apply to the journal pertain.

1 **ABSTRACT.**

2

3 **Background:** Due to the increasing prevalence of kidney transplantation, a greater awareness of variations in
4 the surrounding vasculature is of surgical importance. During embryological development, both the renal and
5 gonadal arteries arise from lateral mesonephric branches of the dorsal aorta. In adults, gonadal arteries are
6 paired vessels that normally arise from the aorta at the level of the second lumbar vertebra.

7

8 **Methods:** Routine cadaveric dissection completed by first-year medical students and dental students
9 incidentally revealed anatomical anomalies.

10

11 **Results:** We describe two cadaveric findings in male cases which demonstrate unilateral and bilateral variations
12 of testicular arteries originating from an aberrant renal artery in one case and an accessory renal artery in the
13 other.

14

15 **Conclusion:** By increasing awareness of anomalous testicular arteries we hope to encourage the
16 standardization of preoperative vasculature exploration to both minimize intra-operative risk to living male
17 kidney donors and increase patients' understanding of potential risks and complications prior to consenting to
18 the procedure providing more accurate information prior to surgery.

19

20 **Key Words:** Renal Transplantation, Congenital Abnormality, Medical Imaging, Dissection.

Accepted, in press

1 INTRODUCTION.

2

3 The number of kidney transplants performed globally has increased each year. The number was 17,611 in
4 2015, 19,061 in 2016, 21,028 in 2017, 22,393 in 2018, and reached a high of 24,273 in 2019.^{1,2} More
5 specifically, the number of living kidney donor transplants has grown over the last decade, with 62% of
6 countries reporting at least a 50% increase.³ The outcome of recipients of deceased donors includes a one
7 year survival rate of 95.4%, five year survival of 79.7%, and adjusted ten year survival rate of 49.2%. In
8 comparison, the outcome of recipients of living donors had a one year survival rate of 98.8%, five year
9 survival of 88.0%, and adjusted ten-year survival rate of 61.5%.² Given the greater potential for survival with
10 living donors, it is important to create a standard screening and informed consent process to increase the
11 safety for living donors, and potentially lead to more individuals feeling safe enough to sign up as living
12 donors.²

13

14 In the embryo, there are three sets of lateral mesonephric arteries that branch off of the aorta: caudal, middle,
15 and cranial. As the kidney ascends from its initial position in the pelvis to its more cranial position in the
16 abdomen, its arterial supply also transitions from caudal to middle to cranial. Normally the last branch of the
17 middle group or the first branch of the caudal group becomes the main renal artery while the rest regress.⁴ It is
18 postulated that if one of the rest of the branches do not regress, that they may persist as accessory renal
19 arteries.⁵ Of the caudal arteries, one will typically persist and differentiate into the gonadal artery. It is speculated
20 that if one of the middle groups of lateral mesonephric arteries persists, this will give rise to a gonadal artery
21 that originates from the main or accessory renal artery rather than the aorta.⁶

22

23 There are numerous possible embryological manifestations of gonadal and renal artery anatomy. There are
24 many proposed classification systems for these manifestations in the literature,⁶⁻⁸ most comprehensively by
25 Kayalvizhi et al. whose proposed a classification system that indicates four primary groups of variations: Group
26 I arising from the abdominal aorta, Group II arising from the renal trunk, Group III arising from a suprarenal
27 branch, and Group IV arising from any other vasculature.⁹ Further classification, they suggest, can be made on
28 the basis of specific branch points in Groups I and II.

29

30 Renal arteries normally arise from the abdominal aorta at the level of the second lumbar vertebra.¹⁰ In both
31 sexes, the gonadal arteries arise from the anterolateral surface of the abdominal aorta, typically below the level
32 of origin of the renal artery but superior to the origin of the inferior mesenteric artery (L3).¹⁰

33

34 In both sexes, the gonadal artery travels retroperitoneally on the superficial surface of the psoas major muscle.¹⁰
35 In males, the gonadal artery is known as the testicular artery and enters the inguinal canal through the deep
36 inguinal ring where it proceeds down to the testes.¹⁰ In addition to supplying oxygenated blood to the testes, the
37 testicular artery is also involved in countercurrent temperature exchange with the pampiniform plexus of veins
38 which functions to maintain a slightly cooler temperature within a very narrow range to accommodate
39 spermatogenesis. In females, the gonadal artery is referred to as the ovarian artery. The ovarian artery travels
40 superficially to the psoas major, down the suspensory ligament of the ovary, enters the mesovarium, and may
41 form an anastomosis with the uterine artery in the broad ligament.¹⁰

1
2
3
4
5
6
7
8
9
10
11
12

A common variation of renal vasculature is the presence of an “accessory renal artery,” which some studies estimate could be prevalent in up to 30% of the general population.¹¹ The accessory renal artery follows the path of the main renal artery to the renal hilum, and usually arises from the aorta either below or above the main renal artery. A second known variation is an “aberrant renal artery.” This vessel differs from an accessory renal artery in that it crosses anteriorly to the inferior vena cava instead of posteriorly.¹²

Variations in renal vasculature are often accompanied by variations in gonadal artery origin. In this report, we will outline the following anomalies of gonadal artery vasculature and how they relate to variations in renal vasculature: gonadal arteries arising from (1) a normal renal artery, (2) an aberrant renal artery, and (3) an accessory renal artery.

Accepted, in-press

1 **METHODS.**

2

3 During cadaveric dissection by first-year medical and dental students at the Department of Anatomy and Cell
4 Biology at New York Medical College, a total of 58 cadavers were dissected during the 2018-2020 academic
5 years. All 58 provided cadavers were well-embalmed and provided for academic dissection. Cadavers were
6 chosen for inclusion in this cross-sectional observational study based on availability sampling and all the
7 provided cadavers were included in the observational study. In 2018, 21 female and 8 male cadavers were
8 dissected. In 2019, 11 male and 18 female cadavers were dissected. Cadavers dissected prior to 2018 were
9 excluded from the study. Cadavers with unidentifiable gonadal arteries due to improper dissection were
10 excluded from our cohort. In routine academic dissection, the retro-peritoneal structures of each cadaver were
11 dissected following the instructions outlined in Grant's dissector.¹³

12

13 The dissection occurred as follows: First, the posterior abdominal viscera were palpated and the parietal
14 peritoneum was removed. The renal fascia and the kidneys were opened and the suprarenal glands were noted.
15 Next, the testicular arteries were identified at the deep inguinal ring. The arteries were dissected cleanly,
16 progressing superiorly along the retroperitoneal space to their origin on the abdominal aorta. The renal veins
17 were then identified and followed to the inferior vena cava. Finally, the renal arteries were identified posteriorly
18 to the renal veins and subsequently followed back to the abdominal aorta. Upon completion of cadaveric
19 dissection, variants of the renal and testicular arteries were noted and recorded.

20

Accepted, in press

1 **RESULTS.**

2

3 One male cadaver (2018) was incidentally identified to have bilateral variants with a left accessory renal artery
4 **(Figure 1e)** from which the left testicular artery originated **(Figure 1i)**, and a single right renal artery from which
5 the right testicular artery originated **(Figure 1o)**. A second male cadaver (2019) was also incidentally identified
6 to have a unilateral variant on the right side where the testicular artery **(Figure 2f)** originated from an aberrant
7 renal artery **(Figure 2c)**. The renal vasculature of the cadaver dissected in 2019 was not observed on the left
8 side due to prior dissection of the entire kidney and associated vasculature.

9

10 In our cohort, 2 out of the 19 males presented with variations of anomalies in renal or testicular vasculature,
11 giving a 10.5% prevalence. There were no anomalies in renal or ovarian vasculature observed in the 38 females
12 of the cohort of 58 cadavers, giving an overall observed prevalence of 3.4% in our cohort.

13

14 Other demographic, clinical, and social characteristics of the cadaver population are not known.

15

16

Accepted, in-prepress

1 DISCUSSION.

3 Classification of variations in testicular and renal arteries

4 Using the Kayalvizhi et al. classification system,¹¹ the variations we note in our cadaver study would be classified
5 as IIB (from an accessory renal branch) and class IIC (from an aberrant renal branch).

7 Prevalence

8 Two of the male cadavers in our cohort of 58 cadavers presented with variations of anomalies in renal or
9 testicular vasculature, suggesting a prevalence of approximately 10.5% among males; no anomalies existed in
10 the female subgroup of our cohort. This is considerably less than some of the reported estimates in the literature,
11 presumably due the small sample size.¹¹ The higher prevalence in males does correspond with previous
12 findings,⁷ with a higher prevalence on the left side (81.23%) compared to the right side in cases with unilateral
13 anomalous arteries.¹⁴ One study found 25% of cases occur bilaterally.¹⁴

15 Method of identification & significance

16 Understanding atypical anatomical presentations of the renal and gonadal vasculature is essential prior to renal
17 and testicular surgery to mitigate risks associated with vascular anomalies. We speculate that the surgical risks
18 posed by the unfamiliar vasculature during nephrectomy, including longer operation times, increased blood loss
19 during surgery, and greater risk of complications associated with unfamiliar vasculature,¹⁵ are greater for male
20 kidney donors because the testicular artery provides the most significant blood flow to the testes. Aside from
21 their surgical significance, the variations in renal vasculature or origin of the gonadal vasculature do not present
22 with any clinical manifestations and are often discovered during surgery or post-mortem.

24 Imaging

25 There is currently no standardized imaging for the preoperative screening of a kidney donor but magnetic
26 resonance imaging (MRI) or computed tomography scan (CT) are commonly used to assess the anatomy of
27 the kidney, vasculature, and urinary collecting system in the living donor.¹⁶ Although necessary for the
28 preoperative work-up, both MRI and CT are considered suboptimal for visualizing anomalous gonadal
29 vasculature involving the kidney.¹⁷ CT Angiography remains the gold standard for visualizing the gonadal and
30 renal vessels, although is not universally used. Doppler ultrasound of the renal hilum is a quick and effective
31 diagnostic procedure that could be alternatively implemented to screen for the presence of atypical renal
32 vasculature prior to surgery for male kidney donors after a statistically significant proof of higher risk to male
33 donors has been established. This method is preferred over conventional sonography as it provides functional
34 and vascular information, locating the presence and blood flow of vessels. It can also be a useful tool to
35 assess the donor organ for fibrosis, masses, and chronic kidney disease.¹⁸ Research suggests that the
36 presence of a gonadal artery with anomalous origin is often associated with variants in renal vasculature.^{15,19}
37 The presence of atypical renal vasculature in the living donor might raise the physician's index of suspicion
38 regarding variants in gonadal vasculature and arteriography can be performed to further investigate the
39 anatomy of the gonadal arteries. As the increasing global rate of kidney transplantation has risen in past
40 decades,² a standardization of screening methods to minimize risks for transplant candidates is of increasing
41 importance.

1
2
3
4
5
6
7
8
9
10
11
12
13
14
15
16
17
18
19
20
21
22
23
24
25
26
27
28
29
30
31
32
33
34
35
36
37
38
39
40
41

In addition to lack of pre-operative imaging, there is currently no standardized informed consent procedure for informed consent for donor nephrectomy and research has shown that donors often make their decision based on moral beliefs and without full knowledge of the scope of potential complications.²⁰

Surgical Risks

Variations in renal and gonadal vasculature are associated with both intraoperative and post-operative risks to living donors. In living donors, if a variation in gonadal vasculature is unknown prior to surgery, it may result in the ligation of the donor's gonadal artery at the surgeon's discretion in the process of obtaining the donor kidney. In the male, the testicular artery provides the most significant blood flow to the region and we speculate that ligation of this artery could contribute to possible risk of complications to the testes following the procedure, including loss of the temperature regulation system of the testes. The ovaries have a dual blood supply supported by the ovarian and uterine arteries, lowering their potential risk of cutting complete supply to the female gonads. Post-operative outcomes of testicular ligation are not well-reported in the literature so the risks of ligation remain unclear; however, the currently available research suggests that the incidence of adverse outcomes to the testes following testicular artery ligation is low.^{13,14,20,21} Vascular variations such as these are of growing significance with the implementation of laparoscopic procedures, as unfamiliar anatomy in the surgical field is a common contributing factor to intraoperative complications.²³ In laparoscopic donor nephrectomy, multiple arteries were associated with longer operation times and increased blood loss during surgery.¹⁹ In surgeries other than donor nephrectomy, certain variants of anomalous gonadal vasculature are absolute contraindications for surgical treatment; for example, a gonadal artery originating from the inferior polar renal artery can be a major contraindication for percutaneous treatment of the syndrome of the pyelo-ureteral junction.¹⁴ Without preoperative awareness of the existence of certain variants in vasculature and the risks associated with them, the donor is left to consent without full knowledge of the scope of potential intraoperative and post-operative complications.

Previously, to reduce the risk of unintentional ligations, surgeons would perform a "time-out" where all key structures are identified. While the implementation of this strategy does decrease the incidences of gonadal artery ligation, the addition of a pre-procedure US-Doppler could cut down on operation time, adding to overall institutional efficiency and over time have a beneficial impact financially due to reduced time per procedure in the operating room.

Limitations

Our estimates for the prevalence of atypical gonadal and renal vasculature are limited by availability sampling and the incidental nature of their discovery. In this observational study, all of the provided cadavers were screened according to our inclusion and exclusion criteria, as previously mentioned. Our cases were discovered by medical students, who are in the process of familiarizing themselves with the procedures of cadaveric dissection and with typical anatomy. This is a potential source of selection bias, as candidates for inclusion may have been damaged in the process; however, no cadavers met exclusion criteria and all were dissected under the direct supervision of physicians. The prevalence results of this sample cannot be generalized to the general population due to the small size and potential of misrepresentation in the sample compared to the general

1 population. We accounted for the limited number of cadavers studied at the school by including data from
2 multiple years to increase our sample size. Furthermore, due to limited access to cadaver demographic
3 information, no conclusions can be made on how these results can be applied to specific demographic
4 populations. Given the frequent clinical insignificance of these anomalies for the general population, much of
5 our knowledge of these variants and their respective prevalence come from post-mortem findings. We
6 acknowledge that our results have limited external validity because of the aforementioned limitations but
7 nevertheless are clinically valuable to raise awareness for the necessity of renal and gonadal vasculature
8 screening.

Accepted, in-press

1 **SUMMARY - ACCELERATING TRANSLATION**

2

3 **Title:** A Cadaveric Study on the Anomalous Origin of Renal and Gonadal Vasculature: An Observational Study.

4 **Main problem to solve:** Due to the increasing prevalence of kidney transplantation, a greater awareness of
5 variations in the surrounding vessels is of importance to surgeons and patients. During development, both the
6 renal and gonadal arteries arise from branches of the same vessels. In adults, gonadal arteries are paired
7 vessels that normally arise from the aorta. Variations in vessels can be detected prior to surgery with imaging,
8 although currently there is no agreed upon standard of pre-surgical screening.

9 **Aim of study:** To illustrate variations in vessels that supply the kidneys and the gonads; to explore the benefits
10 of different imaging modalities.

11 **Methodology:** Routine cadaveric dissection completed by first-year medical students and dental students
12 incidentally revealed anatomical variations.

13 **Results:** We describe two cadaveric findings in male cases which demonstrate unilateral and bilateral variations
14 of testicular arteries originating from an aberrant renal artery in one case and an accessory renal artery in the
15 other.

16 **Conclusions:** By increasing awareness of variations in testicular arteries we hope to encourage the
17 standardization of preoperative vasculature exploration to both minimize intra-operative risk to living male
18 kidney donors and increase patients' understanding of potential risks and complications prior to consenting to
19 the procedure providing more accurate information prior to surgery.

Accepted, in press

1 **REFERENCES.**

- 2 1. Hart A, Lentine KL, Smith JM, Miller JM, Skeans MA, Prentice M, et. al. OPTN/SRTR 2019 Annual
3 Data Report: Kidney. *Am J Transplant.* 2021 Feb;21 Suppl 2:21-137.
- 4 2. United States Renal Data System. (2020). *USRDS Annual Data Report: Epidemiology of kidney*
5 *disease in the United States.* National Institutes of Health, National Institute of Diabetes and Digestive
6 and Kidney Diseases, Bethesda, MD, 2020. Available from: [https://adr.usrds.org/2020/end-stage-](https://adr.usrds.org/2020/end-stage-renal-disease/6-transplantation)
7 [renal-disease/6-transplantation](https://adr.usrds.org/2020/end-stage-renal-disease/6-transplantation). Cited September 26, 2021.
- 8 3. Horvat LD, Shariff SZ, Garg AX; Donor Nephrectomy Outcomes Research (DONOR) Network. Global
9 trends in the rates of living kidney donation. *Kidney Int.* 2009 May;75(10):1088-98
- 10 4. Perez, JA, Torres FG, Toribio AM, Fernandez LK, Hayoun, C, Naranjo ID. Angio CT assessment of
11 anatomical variants in renal vasculature: its importance in the living donor. *Insights Imaging.* 20013;
12 4:199-211.
- 13 5. Sadler, TW. *Langman's medical embryology.* 14th ed. Philadelphia: Lippincot Williams & Wilkins,
14 2015.
- 15 6. Cicekcibasi AE, Salbacak A, Seker M, Ziylan T, Buyukmumcu M, Uysal II. The origin of gonadal
16 arteries in human fetuses: Anatomical variations. *Ann Anat.* 2002;184:275–279.
- 17 7. Machnicki A, Grzybiak M. Variations in testicular arteries in fetuses and adults. *Folia Morphol (Warsz).*
18 1997;56(4):277-85.
- 19 8. Notkovich H. Testicular artery arching over renal vein: clinical and pathological considerations with
20 special reference to varicocele. *Br J Urol.* 1955 Sep;27(3):267-71.
- 21 9. Kayalvizhi I, Narayan RK, Kumar P. Anatomical variations of testicular artery: a review. *Folia Morphol*
22 *(Warsz).* 2017;76(4):541-550.
- 23 10. Moore, K. L., & Dalley, A. F. (1999). *Clinically oriented anatomy.* Philadelphia: Lippincott Williams &
24 Wilkins.
- 25 11. Praveen, Kumar G (2012) Bilateral Superior Accessory Renal Arteries - Its Embryological Basis and
26 Surgical Importance – A Case Report. *J Clinic Case Reports* 2:e105.
- 27 12. Graves, F.T. The aberrant renal artery. *J Anat* 1956 Oct; 90(Pt 4): 553–558.1.
- 28 13. Tank, PW. *Grant's dissector.* 15th ed. Philadelphia: Wolters Kluwer Health/Lippincott Williams &
29 Wilkins; 2013.
- 30 14. Petru B, Elena S, Dan I, Constantin D. The morphology and the surgical importance of the gonadal
31 arteries originating from the renal artery. *Surg Radiol Anat.* 2007 Jul;29(5):367-71.
- 32 15. Das, S. Anomalous renal arteries and its clinical implications. *Bratisl Lek Listy* 2008;109(4):182-4.
- 33 16. Harmath CB, Wood CG 3rd, Berggruen SM, Tantisattamo E. Renal Pretransplantation Work-up,
34 Donor, Recipient, Surgical Techniques. *Radiologic clinics of North America.* 2016;54(2):217–234.
- 35 17. Kok NF, Dols LF, Hunink MG, et al. Complex vascular anatomy in live kidney donation: imaging and
36 consequences for clinical outcome. *Transplantation.* 2008;85(12):1760-1765.
- 37 18. Gameraddin, M. *Ultrasound of the Kidneys: Application of Doppler and Elastography, Essentials of*
38 *Abdominal Ultrasound.* Books on Demand; 2019.
- 39 19. Gesase, A.P. Rare origin of supernumerary renal vessels supplying the lower pole of the left kidney.
40 *Ann Anat.* 2007;189(1):53-8.

- 1 20. Kortram K, Lafranca JA, IJzermans JN, Dor FJMF. The need for a standardized informed consent
2 procedure in live donor nephrectomy: a systematic review. *Transplantation* 2014; 98: 1134–1143.
- 3 21. Chan P, Wright E, Goldstein M. Incidence and postoperative outcomes of accidental ligation of the
4 testicular artery during microsurgical varicocelectomy. *J Urol*. 2005;173(2):482-484.
- 5 22. Hsu CW, et al. Incidence and clinical outcomes of gonadal artery injury during colorectal surgery in
6 male patients. *J Gastrointest Surg*. 2019; 23: 2075-2080.
- 7 23. Gupta R, Gupta A, Aggarwal N. Variations of gonadal veins: embryological prospective and clinical
8 significance. *J Clin Diagn Res*. 2015;9:AC08–AC10.

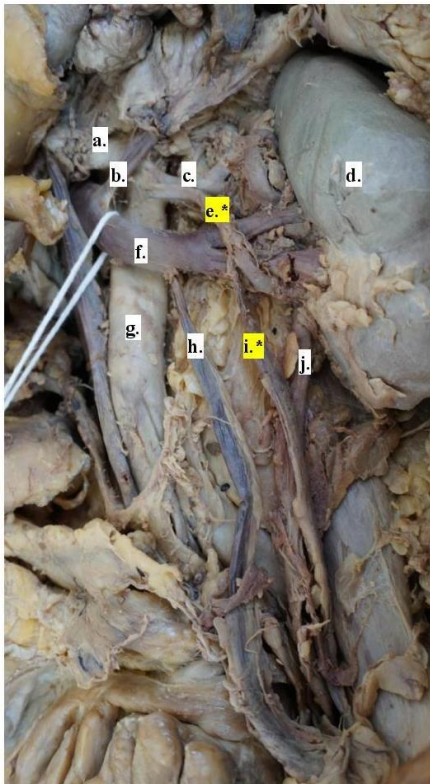
Accepted, in-press

1 **FIGURES AND TABLES.**

2

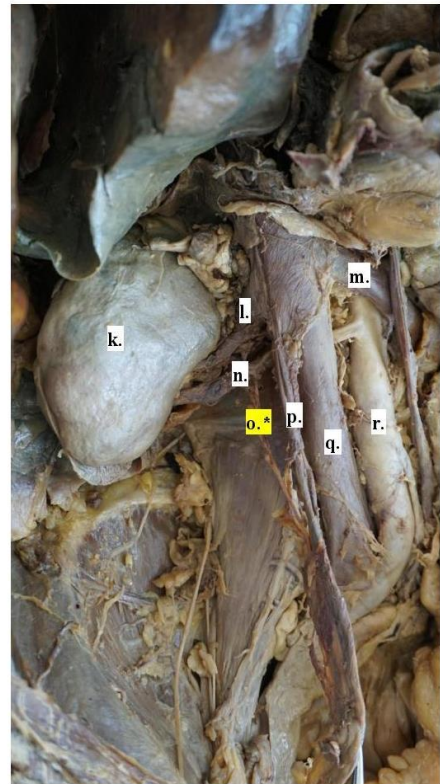
3 **Figure 1.** 2018 Male Cadaver; Left Gonadal Artery with Origin on Accessory Renal Artery, Right Gonadal Artery with
4 Origin on Normal Renal Artery.

5



- a. Superior mesenteric artery
- b. Left adrenal vein
- c. Left renal artery
- d. Left kidney
- e. Left accessory renal artery*
- f. Left renal vein
- g. Aorta
- h. Left gonadal vein
- i. Left gonadal artery*
- j. Ureter

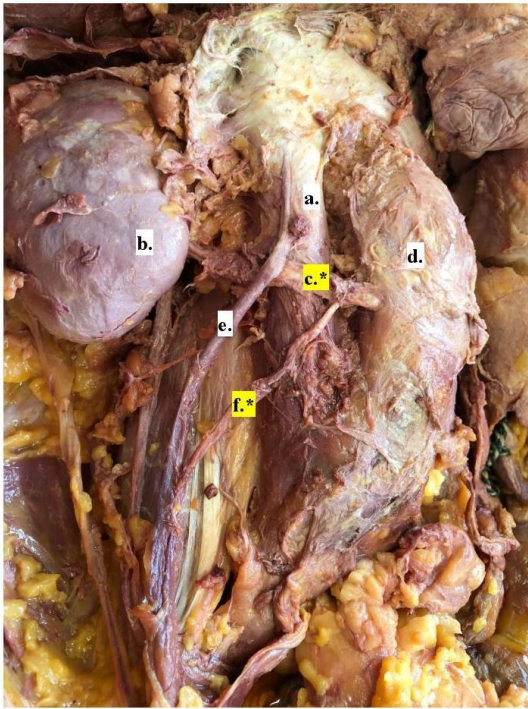
- k. Right kidney
- l. Right renal vein
- m. Left renal vein
- n. Right renal artery
- o. Right gonadal artery*
- p. Right gonadal vein
- q. Inferior vena cava
- r. Aorta



6

Accepte

1 **Figure 2.** 2019 Male Cadaver; Right Gonadal Artery with Origin on Aberrant Renal Artery.



- a. Inferior vena cava
- b. Right kidney
- c. Aberrant right renal artery*
- d. Aorta
- e. Right gonadal vein
- f. Right gonadal artery*

Accepted, in press