

**CASE STUDY****104. Guillain-Barré Syndrome in the Setting of Acute Biliary Pancreatitis: A Rare Clinical Association**Dr. Shaehzeen Arshad<sup>1</sup>, Dr. Haider Iftikhar<sup>1</sup>, Maidah Ilyas<sup>1</sup><sup>1</sup> Pak Emirates Military Hospital, Rawalpindi, Paksitan.

Guillain-Barré syndrome (GBS) is an acute polyneuropathy often triggered by an antecedent infection. Common etiologies of GBS include *C. jejuni*, cytomegalovirus, HIV, influenza, and SARS-CoV-2. Antibodies to these infections can cross-react with shared epitopes on peripheral nerves, causing demyelination or axonal loss. Patients with GBS typically present with bilateral ascending flaccid paralysis, distal paraesthesias, and hyporeflexia.

Acute pancreatitis is an inflammatory condition of the pancreas, often caused by gallstones. Patients classically present with epigastric pain radiating to the back with nausea and vomiting. Pancreatitis is associated with a wide range of systemic complications. Shock, disseminated intravascular coagulation (DIC), sepsis, acute respiratory distress syndrome (ARDS), and renal failure are extensively described in the literature and commonly encountered in critical care settings. Despite the substantial body of work done on pancreatitis complications, one that remains absent from the literature is GBS.

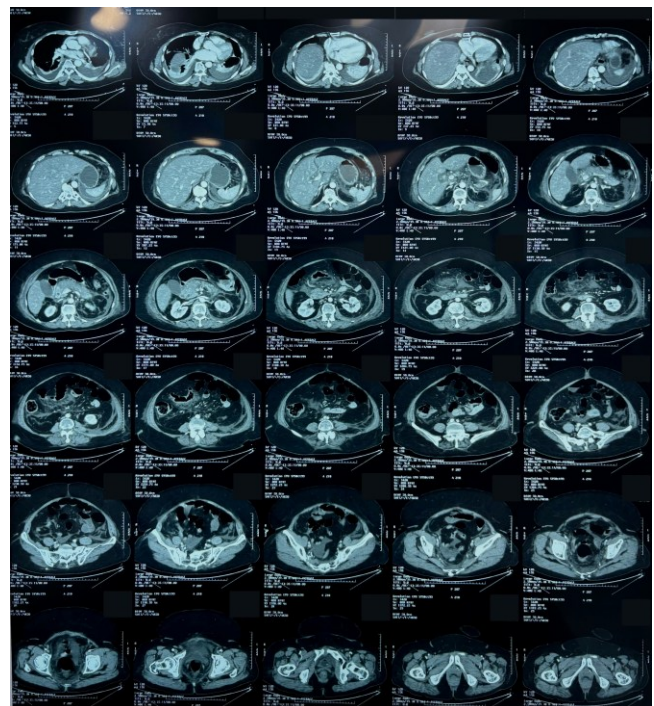
**The Case:** We report the case of a 67-year-old female with ischemic heart disease, hypertension, and megaloblastic anemia. She presented to the ER of a local hospital with epigastric pain radiating to the back and multiple episodes of vomiting. Ultrasound revealed a bulky pancreas and gallbladder mucocele. She was diagnosed with acute biliary pancreatitis (BISAP score 4) and admitted to the surgical ward. After developing persistent increased work of breathing, she was shifted to the ICU, where she was intubated. Contrast-enhanced CT abdomen demonstrated pancreatic swelling, peripancreatic fat stranding, inflammatory extension to the transverse colon, and a 4.2 × 2.3 cm hypoperfused area suggestive of early necrosis. Her clinical course was further complicated by the development of ARDS and acute kidney injury requiring hemodialysis. She remained on mechanical ventilation for 8 days. After extubation, it was noted that she was unable to lift her upper and lower limbs against resistance. Reflexes were absent in all limbs, but sensations were intact. The CT brain was unremarkable. Cerebrospinal fluid analysis showed a normal protein count (24.3 mg/dl) and a raised glucose level (111 mg/dl). Suspecting critical illness polyneuropathy, nerve conduction studies and electromyography were done. However, the results were consistent with the AMSAN variant of GBS. Plasma exchange (PLEX) with albumin replacement was started. A total of 5 sessions were done over the course of 2 weeks. Despite treatment, the patient's respiratory effort continued to decline, developing type II respiratory failure. She was managed on BiPAP as she did not consent to reintubation. After 2 weeks, the patient succumbed to her illness.

**Conclusion**

This case demonstrates a rarely reported association between acute pancreatitis and GBS. In the ICU setting, new-onset neuromuscular

weakness is often attributed to critical illness polyneuropathy. However, this case shows the importance of considering GBS in the differentials and performing electrophysiological studies to achieve an accurate diagnosis. Early recognition is crucial: studies show that PLEX is most effective when started within 7 days of symptom onset. Timely initiation of therapy can lead to improved functional outcomes. Further research is required to determine any potential shared immune-related mechanisms between acute pancreatitis and GBS and to better define management strategies in these patients.

**Figure 1.** Contrast-Enhanced Computed Tomography of the Abdomen and Pelvis (Axial Views).



*This work is licensed under a [Creative Commons Attribution 4.0 International License](https://creativecommons.org/licenses/by/4.0/)*

ISSN 2076-6327

This journal is published by [Pitt Open Library Publishing](https://pittopenlibrarypublishing.com/)

**Pitt** Open Library Publishing