

21. HIGH ALTITUDE PULMONARY EDEMA IN A NATIVE HIGHLANDER: A CASE REPORT FROM NEPAL

Ishwor Thapaliya¹, Adesh Kantha², Krishna Datta Bhatta², Aakash Deo², Dilip Sharma Banjade³, Sushil Kumar Yadav²

¹Institute of Medicine TU Teaching Hospital

²Tribhuvan University, Institute of Medicine, Maharajgunj, Nepal

³Universal College of Medical Science, Bhairahawa, Nepal

BACKGROUND: High altitude pulmonary edema (HAPE) is a non-cardiogenic pulmonary edema, that usually occurs in unacclimatized lowlanders rapidly ascending above 2,500-3,000 m and in highlanders returning from lower altitudes, with both forms likely sharing the same pathophysiology. Its incidence among Himalayan trekkers and Alp's climbers is approximately 4%, often varying with rate of ascent. It usually manifests within 2–4 days of arriving at altitudes exceeding 2,500 meters. The factors predisposing HAPE include prior respiratory infection, rapid ascent, prior history of HAPE, genetic predisposition. Patients with HAPE exhibit increased pulmonary artery pressures, normal left atrial pressure, heightened pulmonary vasoreactivity to hypoxia, and often benefit from treatments lowering pulmonary artery pressures. **THE CASE:** A 41-year-old male of Rai ethnicity, born and raised in the Himalayan region of Nepal began experiencing shortness of breath during his ascent of Mount Everest at around 5,000 meters. The individual, currently employed as a trekking porter, had previously descended to an altitude of 3,420 meters for 2 weeks before commencing his ascent. He reported to have progressively worsening shortness of breath. After the onset of symptoms, he started to descend during which he fell unconscious and was brought to a hospital in Lukla. He had a low Glasgow Coma Scale score of 3/15 and SpO₂ could not be determined by pulse oximetry. At the hospital, he quickly regained consciousness after receiving supplemental oxygen. He was then referred to the tertiary care center in Kathmandu for further evaluation and treatment. At the emergency department, he reported progressive shortness of breath, worsening from MMRC grade II to IV, and orthopnea. He had a similar episode three years prior and no known co-morbidities. Vital signs were stable with oxygen saturation (SpO₂) of 81% in ambient air. Physical examination revealed bilateral wheezes and crackles on chest auscultation. Neurological and abdominal examinations were normal. Laboratory analysis revealed neutrophilia (80%), lymphocytopenia (15%), leukocytosis (14,900 cells/mm³), elevated serum urea (9.4 mmol/l), and high Alanine Transaminase (86 U/l). Liver and renal function tests were normal. Arterial blood gas (ABG) analysis revealed a low blood pH of 7.292. Sputum, blood, and urine cultures were negative for bacteria and fungi. He was transferred to the ICU for high-concentration oxygen therapy. ABG analysis was performed on a daily basis, with results illustrated in figure 1. He was intubated and mechanically ventilated for 4 days. Initially, chest x-ray was performed which shows pulmonary infiltrates in both lungs indicative of pulmonary edema as shown in figure 2. Throughout his ICU stay, he received iv antibiotics, CCBs and diuretics. By day 3, his crackles had significantly diminished, and a follow-up chest radiograph demonstrated notable improvement (Figure 3). After 8 days, he was

transferred to the respiratory medicine ward for 2 days of observation before discharge. **CONCLUSION:** Despite being physiologically adapted to high altitude conditions, native highlanders and people with prior history of HAPE may still be susceptible to developing high altitude pulmonary edema. Immediate treatment includes supplemental oxygen, hyperbaric treatment, or rapid descent. Nifedipine and dexamethasone can be used for HAPE prophylaxis.

Figure 1: Daily Arterial Blood Gas (ABG) Analysis in a Patient with High Altitude Pulmonary Edema (HAPE) During ICU Management.

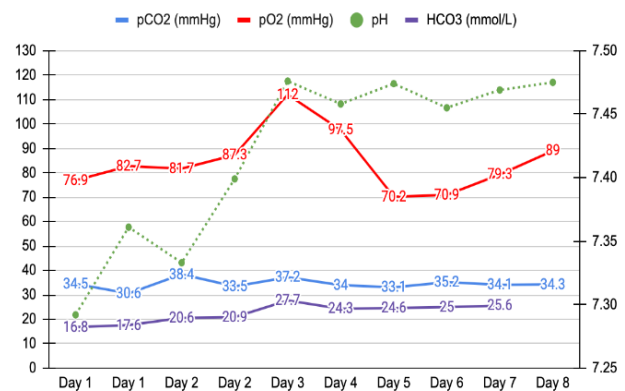
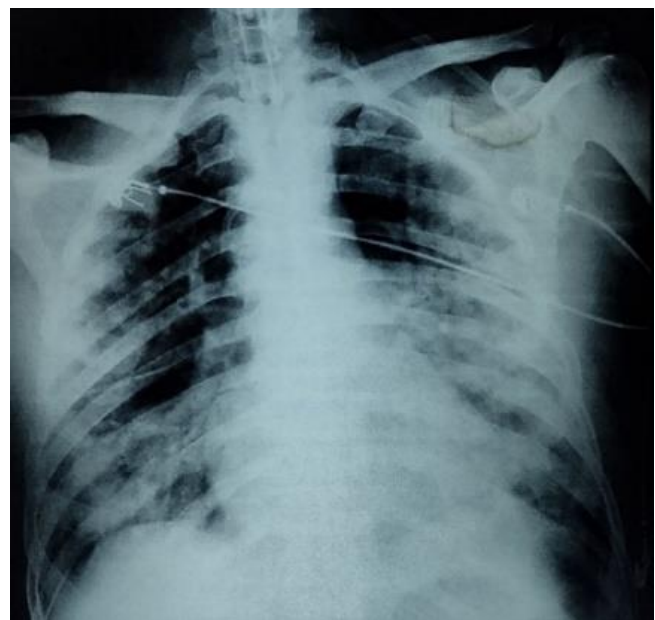


Figure 2: Initial Chest X-Ray Demonstrating Bilateral Pulmonary Infiltrates Indicative of High-Altitude Pulmonary Edema (HAPE).



Key Words: High altitude pulmonary edema, Acclimatization, Highlanders.