

## 68. DIAGNOSTIC CHALLENGE OF PAROXYSMAL NOCTURNAL HEMOGLOBINURIA (PNH) WITH APLASTIC ANEMIA: A CASE REPORT

Priyanshi Maurya<sup>1</sup>, Anjali Bhardwaj<sup>1</sup>, Rahul Singh Bisht<sup>1</sup>, Arusha Desai<sup>1</sup>, Thirugnanasambandam Thayumanavan<sup>1</sup>, Ram Trehan<sup>2</sup>

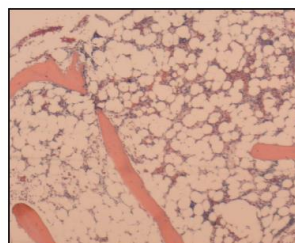
<sup>1</sup> MBBS, Armed Forces Medical College, Pune, India

<sup>2</sup> MD, Greater Washington Oncology Associates, Maryland, USA

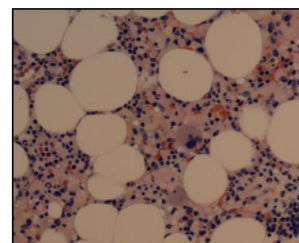
**Background:** Paroxysmal Nocturnal Hemoglobinuria (PNH) is a rare, acquired blood disorder caused by somatic mutations in the phosphatidylinositol glycan protein A (PIG-A) gene within hematopoietic stem cells. This mutation impairs the production of glycosylphosphatidylinositol (GPI) anchor proteins CD55 and CD59, which regulate complement activity. Their deficiency leads to uncontrolled complement activation, resulting in hemolysis and other PNH manifestations, including pancytopenia and aplastic anemia. Pancytopenia is a reduction in all three blood cell types below normal ranges, while aplastic anemia is pancytopenia with hypo cellular bone marrow. Aplastic anemia can create an environment conducive to PNH clone expansion. PNH's close association with aplastic anemia causes a diagnostic dilemma as to whether it is a cause or effect of aplastic anemia complicating the determination of the primary disease. Here, we present a case of a 39-year-old woman with transfusion-dependent pancytopenia, later diagnosed with PNH and aplastic anemia. **Case Report:** A 39-year-old woman presented with shortness of breath, palpitations, light-headedness, easy bruising, and heavy menstrual bleeding. She experienced significant fatigue and a near-fainting episode. Initial blood tests revealed pancytopenia, leading to an emergency department referral. Her medical history included Vitamin B12 deficiency, hypothyroidism, galactosemia, anxiety disorder, and a previous COVID-19 infection. On examination, she was alert but fatigued and dizzy, with pallor, hypotension (99/37 mm Hg), and bradycardia (57/min). Lab tests showed severe anemia (hemoglobin 4.8 g/dL), thrombocytopenia (platelets 22,000/ $\mu$ L), and signs of hemolysis (elevated LDH and low haptoglobin). Despite treatment with intravenous Vitamin B12 and steroids, there was no improvement. Blood tests for Epstein-Barr and Parvovirus were positive, but methyl prednisone and intravenous immunoglobulin treatment had no significant effect. This made it clear that her

pancytopenia was not due to these viral infections. A bone marrow biopsy (image 1) revealed hypo cellular marrow with decreased trilineage hematopoiesis, and there was no evidence of myeloid or lymphoid neoplasms. She was diagnosed with aplastic anemia based on these findings. Given the persistence of pancytopenia and the absence of other identifiable causes, a workup for PNH was initiated. Flow cytometry confirmed the presence of GPI-deficient cells, consistent with a diagnosis of PNH with immune-mediated aplastic anemia. The patient was started on Pegcetacoplan, a proximal complement inhibitor, which led to significant clinical improvement. However, due to persistent thrombocytopenia, she was also considered for a bone marrow transplant and referred for further evaluation. **CONCLUSION:** PNH is a rare hematological disorder that can present with diverse clinical features, including pancytopenia and aplastic anemia. The diagnosis is challenging and requires a thorough evaluation to exclude other potential causes. In this case, the patient's pancytopenia was initially attributed to various reversible causes, but the persistence of symptoms and detailed investigations ultimately led to the diagnosis of PNH. Treatment with complement inhibitors like Pegcetacoplan can significantly improve clinical outcomes, although bone marrow transplantation remains the only curative option. Close monitoring and individualized treatment plans are essential for managing the complications associated with PNH.

**Figure:** Bone Marrow Biopsy Findings in Paroxysmal Nocturnal Hemoglobinuria with Aplastic Anemia.



Core biopsy: hypocellular marrow for age



Core: mixed hematopoiesis

**Key Words:** (Hemoglobinuria, Paroxysmal), (Anemia, Aplastic), Pancytopenia.